



Vitamin B12, demyelination, remyelination and repair in multiple sclerosis

Ariel Miller^{a,*}, Maya Korem^a, Ronit Almog^b, Yanina Galboiz^a

^a*Division of Neuroimmunology and Multiple Sclerosis Center, Carmel Medical Center, Haifa 34362, Israel*

^b*Department of Community Medicine and Epidemiology, Rappaport Faculty of Medicine and Research Institute, Technion, Carmel Medical Center, Haifa, Israel*

Abstract

Multiple Sclerosis (MS) and vitamin B12 deficiency share common inflammatory and neurodegenerative pathophysiological characteristics. Due to similarities in the clinical presentations and MRI findings, the differential diagnosis between vitamin B12 deficiency and MS may be difficult. Additionally, low or decreased levels of vitamin B12 have been demonstrated in MS patients. Moreover, recent studies suggest that vitamin B12, in addition to its known role as a co-factor in myelin formation, has important immunomodulatory and neurotrophic effects. These observations raise the questions of possible causal relationship between the two disorders, and suggest further studies of the need to close monitoring of vitamin B12 levels as well as the potential requirement for supplementation of vitamin B12 alone or in combination with the immunotherapies for MS patients.

© 2005 Elsevier B.V. All rights reserved.

Keywords: Immunomodulation; Immunotherapy; Interferon- β ; Multiple sclerosis; Vitamin B12

1. Physiology of Vitamin B12

Vitamin B12, also known as Cobalamin, is a complex organometallic compound in which a cobalt atom is situated within a corrin ring, a structure similar to the porphyrin from which heme is formed. Unlike heme, however, cobalamin cannot be synthesized in the human body and must be supplied in the diet. The only dietary source of cobalamin is animal products such as meat and dairy foods. The minimum daily requirement for cobalamin is about 2.5 μ g.

During gastric digestion, cobalamin is released from the ingested food and forms a stable complex with gastric R-binder, a glycoprotein found in various secretions, phagocytes, and plasma. Upon entering the duodenum, the complex is digested releasing the cobalamin, which then binds to intrinsic factor (IF), a glycoprotein produced by the parietal cells of the stomach. The cobalamin–IF complex is resistant to proteolytic digestion and reaches the distal ileum, where it is absorbed by specific receptors. In the ileal

mucosal cell the IF is destroyed and the cobalamin is transferred to transcobalamin (TC) II. The cobalamin–TCII complex is then secreted into the circulation, from which it is rapidly taken up by the liver, bone marrow, and other cells.

Cobalamin is an essential cofactor for two enzymes in human cells: methionine synthase, which catalyzes the conversion of homocysteine to methionine, and methylmalonyl-CoA synthase, which catalyzes the conversion of methylmalonyl CoA to succinyl CoA (reviewed in [1]).

2. Vitamin B12 deficiency

In view of the minimal daily requirement, about 3–6 years are needed for a normal individual to become cobalamin-deficient if absorption is ceased abruptly.

The various reasons for cobalamin deficiency include mainly inadequate intake (vegetarians) and malabsorption. Malabsorption may be caused by defective release of cobalamin from food, inadequate production of IF such as in cases of pernicious anemia, disorders of terminal ileum, and competition for cobalamin such as in cases of intestinal worms and blind-loop syndrome [1].

* Corresponding author. Tel.: +972 4 8250 851; fax: +972 4 8250 909.

E-mail addresses: millera@tx.technion.ac.il, milleras@netvision.net.il (A. Miller).

Pernicious anemia is considered a major cause of cobalamin deficiency. It is caused by the absence of IF either because of gastric mucosa atrophy or autoimmune destruction of parietal cells. The incidence of pernicious anemia is substantially increased in patients with other diseases of immunologic origin. Abnormal circulating antibodies (Abs) can be found in pernicious anemia patients. 90% express anti parietal cell Abs and 60% express anti IF Abs, though the disease is thought to be cytotoxic T-cell mediated [2].

Impairment in the conversion of homocysteine to methionine leads to a defect in DNA synthesis and a megaloblastic maturation pattern as well as to a defective production of choline and choline containing phospholipids, which in part are responsible for the neurologic complications of cobalamin deficiency. Increase in tissue levels of methylmalonyl CoA and its precursor leads to formation and incorporation of non-physiologic fatty acids into neuronal lipids. Such lipids are found in myelin sheaths and their damage can be in part responsible for the neurologic complications of cobalamin deficiency [1,3].

The clinical features of cobalamin deficiency involve the hematologic system, the gastrointestinal (GI) tract and the nervous system.

The hematologic manifestations are mainly the result of anemia, although very rarely purpura may appear, and may include weakness, light-headedness, vertigo, tinnitus, palpitations, angina, and symptoms of congestive failure.

The GI manifestations reflect the effect of cobalamin deficiency on the rapidly proliferating GI epithelium, and may include sore tongue, anorexia, moderate weight loss, diarrhea, and other GI complaints.

The neurologic manifestations begin pathologically with demyelination, followed by axonal degeneration and eventual irreversible damage due to axonal death [1]. The spinal cord, brain, optic nerves, and peripheral nerves may all be affected by cobalamin deficiency. The spinal cord is usually affected first and often exclusively. The term subacute combined degeneration (SCD) is customarily reserved for the spinal cord lesion of vitamin B12 deficiency and serves to distinguish it from other types of spinal cord diseases that happen to involve the posterior and lateral columns. The patient first notices general weakness and paresthesias. As the illness progresses the gait becomes unsteady and stiffness and weakness of the limbs develop, as well as ataxic paraplegia. The Lhermitte phenomenon is not an uncommon finding. Mental signs are frequent and range from irritability, apathy, somnolence and emotional instability to marked confusional or depressive states. Visual impairment due to optic neuropathy may occasionally be the earliest or sole manifestation.

The pathologic lesions, mainly involving the myelin sheath, are not limited to specific systems of fibers but are scattered irregularly through the white matter [3]. It should be emphasized that a neurologic disease may occur in a patient with a normal hematocrit and normal red blood cell indexes [1].

The diagnosis of cobalamin deficiency is typically based on measurement of serum vitamin B12 level. However, about 50% of patients with subclinical disease have normal B12 levels. A more sensitive method of screening for cobalamin deficiency is measurement of methylmalonic acid and homocystein blood levels, which are increased early in vitamin B12 deficiency. However, elevated methylmalonic acid and homocystein blood levels seem to be related more to folic acid than to vitamin B12 deficiency [4]. Use of the Schilling test for detection of pernicious anemia has been replaced for the most part by serologic testing for parietal cell and IF Abs [5,6].

In a study evaluating the neuro-physiological and magnetic resonance imaging (MRI) changes in patients presenting with vitamin B12 deficiency and neurological syndromes, the evoked potentials and MRI changes were found to be consistent with focal demyelination of white matter in the spinal cord and optic nerve [7]. MRI imaging of the brain and spinal cord demonstrates, in some cases of vitamin B12 deficiency, a typical pattern of white matter degeneration commonly seen in MS, such as extensive areas of T2 high-intensity signal in the periventricular white matter [8,9].

3. Vitamin B12 deficiency and multiple sclerosis

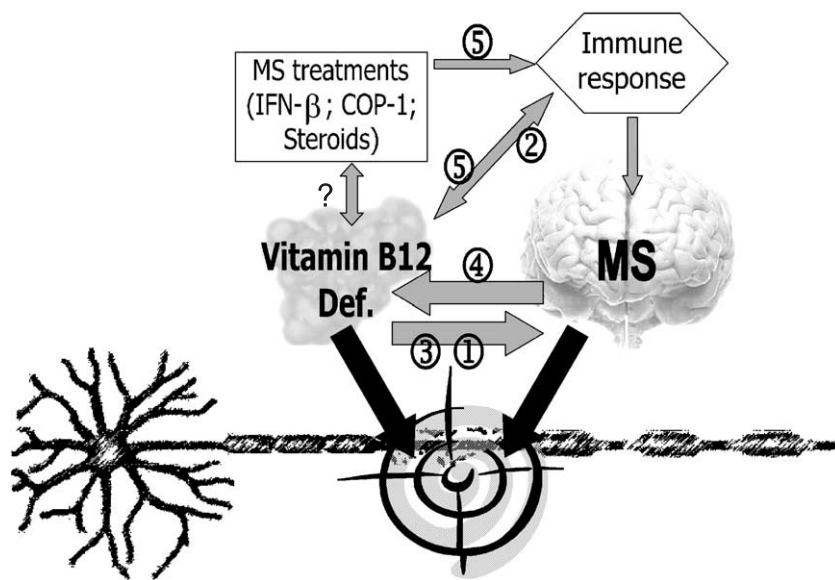
Due to the above-mentioned clinical and MRI characteristics, the differential diagnosis between vitamin B12 deficiency and MS may be difficult [10]. Additionally, low or decreased levels of vitamin B12 have been demonstrated in MS patients. Several studies have demonstrated significantly reduced serum levels of vitamin B12 as well as macrocytosis in MS patients [11–13]. A different study demonstrated significantly reduced levels of vitamin B12 in the cerebrospinal fluid (CSF) of MS patients with a trend towards reduced levels in the serum [14]. On the other hand, a study evaluating methylmalonic acid levels in MS patients did not confirm B12 deficiency as a common feature of the disease [15], and increased plasma homocysteine levels without signs of vitamin B12 deficiency, in patients with multiple sclerosis was described recently by others [16]. Nonetheless, positive findings of oligoclonal bands in CSF of patients with clinical phenotype of CNS demyelination are supportive of MS vs. vitamin B12 deficiency.

As mentioned above, vitamin B12 deficiency leads to defective formation of the myelin sheath, due to incorporation into neuronal lipids of non-physiologic fatty acids [3] as well as to defective methylation of myelin basic protein (MBP), a major component of CNS myelin [17,18]. Cobalamin deficiency may serve as a metabolic basis for MS by leading to formation of defective central myelin which triggers the autoimmune process. Additionally, recent studies support existence of important immunoregulatory effects of vitamin B12, including modulation of

cytokines $\text{TNF}\alpha$ activity [19–22]. In line with these mechanisms, cobalamin deficiency may exacerbate existing MS by worsening the inflammatory and demyelination processes, as well as slowing remyelination and repair. On the other hand, aberrant activation and proliferation of immunocompetent cells, having an enhanced demand for B-vitamins [22], and repeated or continuous inflammatory and demyelinating processes followed by endogenous attempts for remyelination and repair, increase vitamin B12 consumption and may lead to its deficiency. Thus, multiple levels of inter-relationship (including aspects of association, causality or aggravation) between cobalamin deficiency and MS, may be suggested (Fig. 1), but yet to be confirmed. Noteworthy, hyperhomocysteinemia, which is associated with an increased risk of atherosclerosis, neuro-vascular and neurodegenerative processes, which seem to take place also in MS, is triggered by vitamin B12 deficiency as well as by Th1-type immune response which is a characteristic of MS [22], adding to the complexity of these biological interactions.

Of note, the first reports about possible role of B12 in the pathogenesis of MS came out more than three decades ago, but the small number of published studies that examined the association and the weak study designs and methodological problems that characterize these studies make it impossible to derive a causal inference about the association. The association was determined only in cross-sectional case-control study designs and was not tested in prospective or nested case-control designs, thus lacking the ability to answer one of the basic and necessary causality criteria that the cause must precede the effect in time.

The studies were done in the clinical surrounding and the selection of cases and controls was based mainly on high accessibility to the populations and not on methodological considerations. The inclusion of cases was not based on strict diagnostic criteria but usually on physician diagnosis and the control groups were usually historic controls or hospital staff controls. The possibility of selection bias as a possible explanation of the results cannot be ruled out.



1. Vitamin B12 deficiency may lead to dysformed myelin which may become a target for autoimmune attacks → aggravating MS
2. Vitamin B12 deficiency is associated with reduction of its immunomodulatory activity → aggravating MS
3. Vitamin B12 deficiency is associated with reduction of its neurotrophic activity → aggravating MS
4. Inflammatory and demyelinating activity in MS is associated with attempts of remyelination leading to consumption of Vitamin B12 → Vitamin B12 Deficiency
5. Immunotherapies induce Th1 to Th2 shift that may lead to:
 - a. Increase repair and consumption of Vitamin B12 → Vitamin B12 Deficiency
 - b. Possible induction of auto Abs including anti IF and anti PC → pernicious anemia and Vitamin B12 deficiency

Fig. 1. Potential associations between vitamin B12 levels and multiple sclerosis.

The importance of strict diagnostic criteria for MS and B12 deficiency becomes even more important in the last decade as it was shown that MRI imaging in B12 deficiency patients can be very similar to MRI changes in MS, increasing the possibility of diagnosis misclassification between the two diseases as a possible explanation of the association. Some of the studies used non-specific hematological and metabolic changes associated with B12 deficiency (macrocytosis, increased plasma or CSF homocystein) as a marker for B12 deficiency, but no one tested the all spectrum of laboratory, metabolic, hematological, gastroenterological and neurological changes associated with B12 deficiency.

The possibility that B12 has no causal contribution in the etiology of MS but rather that the association is a result of confounding effect of a third genetic or environmental factor cannot be ruled out on the basis of current data. The studies did not use multivariate models for the control of possible cofounders like demographic, dietary and other lifestyle characteristics, probably because such data was not collected. It is timely for the conduction of a well-designed prospective or nested case-control study to assess the causal relationship of these two disorders.

4. Multiple sclerosis therapy and vitamin B12

High dose methylprednisolone therapy of MS patients was reported to lead to a significant decrease in vitamin B12 CSF levels and to a trend of reduction in serum B12 levels [23]. Immune-mediated therapy of MS with either Copaxone (Cop-1), Interferon- β (IFN- β), or immuno-suppressive agents leads, according to a large number of studies [24–27], to a Th1 to Th2 immune-deviation. A shift to a Th2 immune profile entails the risk of over-activating the humoral arm of the immune system, thus leading to antibody mediated autoimmune disorders.

Pernicious anemia was recently reported in a patient treated with interferon- α for chronic hepatitis C [24]. Treatment with Interferon- β has been reported to induce elevated titers of anti-nuclear, anti-smooth muscle and other auto Abs [28,29], subacute thyroiditis [30], and Graves disease [31,32]. One such Th2 autoimmune disorder may result in elicitation of auto Abs specific to parietal cells or IF, leading to pernicious anemia and associated vitamin B12 deficiency. A study recently conducted in our laboratory [33] demonstrated that immuno-therapy of MS patients with IFN- β and to a lesser extend with Cop-1 is associated with a significant reduction in vitamin B12 serum levels. This reduction, however, did not appear to be related to aberrant induction of self-Abs, but may be secondary to therapy-mediated suppression of the inflammatory processes while enhanced repair mechanisms, which are associated with enhanced consumption of vitamin B12 (Fig. 1). This is of special interest due to recent evidence supporting neurotrophic action of vitamin B12 [34].

However, independently of the mechanism(s) by which vitamin B12 levels may be affected by MS and its therapies, if confirmed, these findings emphasize the need for meticulous follow-up of vitamin B12 levels prior to and during immuno-therapy and for evaluation of the necessity of vitamin B12 supplementation for MS patients. This latter issue has received further support recently in a study of Mastronardi et al. [35] who demonstrate dramatic improvements of clinical, histological, and laboratory parameters in in-vivo experimental models of demyelinating disease, through combination therapy with IFN- β plus vitamin B12.

References

- [1] Babior BM, Bunn HF. Megaloblastic anemias. In: Braunwald E, Fauci AS, Kasper DL, Hauser SL, Longo DL, Jameson JL, editors. *Harrison's principles of internal medicine*, 15th ed. New-York: McGraw-Hill; 2001. p. 674–80.
- [2] Babior BM. The megaloblastic anemias. In: Butler E, et al., editor. *Williams hematology*, 6th ed. New York: McGraw-Hill; 2000.
- [3] Victor M, Ropper AH. Diseases of the nervous system due to nutritional deficiency. *Adams and Victor's principles of neurology*, 7th ed. New York: McGraw-Hill; 2001. p. 1218–22.
- [4] Lee BJ, Lin PT, Liaw YP, Chang SJ, Cheng CH, Huang YC. Homocysteine and risk of coronary artery disease: folate is the important determinant of plasma homocysteine concentration. *Nutrition* 2003;19:577–83.
- [5] Oh R, Brown DL. Vitamin B12 deficiency. *Am Fam Physician* 2003; 67:979–86.
- [6] Lindenbaum J, Savage D, Stabler S. Diagnosis of cobalamin deficiency: relative sensitivity of serum cobalamin, methyl malonic acid and total homocysteine concentrations. *Am J Hematol* 1990;34: 99–107.
- [7] Misra UK, Kalita J, Das A. Vitamin B12 deficiency neurological syndromes: a clinical MRI and electrodiagnostic study. *Electromyogr Clin Neurophysiol* 2003;43:57–64.
- [8] Scherer K. Neurologic manifestations of vitamin B12 deficiency. *NEJM* 2003;348:2208.
- [9] Katsaros VK, Glocker FX, Hemmer B. MRI of spinal cord and brain lesions in subacute combined degeneration. *Neuroradiology* 1999;41: 387.
- [10] Ghezzi A, Zaffaroni M. Neurological manifestations of gastrointestinal disorders, with particular reference to the differential diagnosis of multiple sclerosis. *Neurol Sci* 2001 (Nov);22(Suppl. 2):S117–22.
- [11] Reynolds EH, Bottiglieri T, Laundry M, Crelline F, Kirker SG. Vitamin B12 metabolism in multiple sclerosis. *Arch Neurol* 1992; 49:649–52.
- [12] Najim Al Din AS, Khojoli M, Habbosh H, Farah S, Idris AR, Al-Muhtasib F. Macrocytosis in multiple sclerosis: a study in 82 de novo Arab patients. *J Neurol Neurosurg Psychiatry* 1991;54:415–6.
- [13] Crellin RF, Bottiglieri T, Reynolds EH. Multiple sclerosis and macrocytosis. *Acta Neurol Scand* 1990;81:388–91.
- [14] Nijst TQ, Hommes OR, Weavers RA, Schoonder-Waldt HC, De Haan AFJ. Vitamin B12 and folate levels of serum and cerebrospinal fluid in multiple sclerosis and other neurological disorders. *J Neuro Neurosurg Psychiatry* 1990;53:951–4.
- [15] Goodkin DE, Jacobsen DW, Galvez N, Daughtry M, Secic H, Green R. Serum cobalamin deficiency is uncommon in multiple sclerosis. *Arch Neurol* 1994;54:1110–4.
- [16] Vrethem M, Mattsson E, Hebelka H, Leerbeck K, Osterberg A, Landtblom AM, et al. Increased plasma homocysteine levels without signs of vitamin B12 deficiency in patients with multiple sclerosis

- assessed by blood and cerebrospinal fluid homocysteine and methylmalonic acid. *Mult Scler* 2003;9:239–45.
- [17] Shevell MI, Rosenblatt DS. The neurology of cobalamin. *Neurol Sci* 1990;19:472.
- [18] Allen RH. Metabolic abnormalities in cobalamin (vitamin B12) and folate deficiency. *FASEB J* 1993;7:1344.
- [19] Peracchi M, Bamonti Catena F, Pomati M, De Franceschi M, Scalabrino G. Human cobalamin deficiency: alterations in serum tumour necrosis factor-alpha and epidermal growth factor. *Eur J Haematol* 2001;67:123–7.
- [20] Calder PC, Kew S. The immune system: a target for functional foods? *Br J Nutr* 2002;88(Suppl. 2):S165–77.
- [21] Miller JW. Vitamin B12 deficiency, tumor necrosis factor-alpha, and epidermal growth factor: a novel function for vitamin B12? *Nutr Rev* 2002;60:142–4.
- [22] Schroecksnadel K, Frick B, Wirleitner B, Winkler C, Schennach H, Fuchs D. Moderate hyperhomocysteinemia and immune activation. *Curr Pharm Biotechnol* 2004;5:107–18.
- [23] Frequin S, Wavers RA, Braam M, Barkhof F, Hommes GR. Decreased vitamin B12 and folate levels in cerebrospinal fluid and serum of multiple sclerosis patients after intravenous methylprednisolone. *J Neurol* 1993;240:305–8.
- [24] Smith DR, Balashov KE, Hafler DA, Khoury SJ, Weiner HL. Immune deviation following pulse cyclophosphamide/methylprednisolone treatment of multiple sclerosis: increased interleukin-4 production and associated eosinophilia. *Ann Neurol* 1997;42:313–8.
- [25] Miller A, Shapiro S, Gershtein R, Kinarty A, Rawashdeh H, Honigman S, et al. Treatment of multiple sclerosis with copolymer-1 (copaxone): implicating mechanisms of Th1 to Th2/Th3 immune-deviation. *J Neuroimmunol* 1998;92:113–21.
- [26] Kozovska ME, Hong J, Zang YCQ, Li S, Rivera VM, Killian JM, et al. Interferon beta induces T-helper 2 immune deviation in MS. *Neurology* 1999;53:1687–92.
- [27] Borgia G, Reynaud L, Gentile I, Borrelli F, Cerini R, Ciampi R, et al. Pernicious anemia during IFN-alpha treatment for chronic hepatitis C. *J Interferon Cytokine Res* 2003;23:11–2.
- [28] Nousari HC, Asadi AK, Tausk FA. Subacute cutaneous lupus erythematous associated with interferon beta 1a. *Lancet* 1998;352:1825–6.
- [29] Durelli L, Ferrero B, Oggero O, Verdun E, Bongioanni MK, Gentile E, et al. Autoimmune events during interferon beta 1b therapy for multiple sclerosis. *J Neurol Sci* 1999;162:74–83.
- [30] Kreiss Y, Cohen O, Pras E, Achiron A. Subacute thyroiditis in a patient with multiple sclerosis treated with interferon beta 1a. *Neurology* 1999;53:1606.
- [31] Schwid SR, Goodman AD, Mattson DH. Autoimmune hyperthyroidism in patients with multiple sclerosis treated with interferon beta 1b. *Arch Neurol* 1997;54:1169–70.
- [32] Rotondi M, Mazziotti G, Biondi B, Mangallena G, Del Buono AD, Montella P, et al. Long term treatment with interferon beta therapy for multiple sclerosis and occurrence of graves disease. *J Endocrinol Invest* 2000;23:321–4.
- [33] Korem M, Miller A. Vitamin B12 levels and auto-antibody formation associated with interferon-β and Copaxone therapy in multiple sclerosis patients. *Proceedings of the ECTRIM*, 2001.
- [34] Scalabrino G, Buccellato FR, Veber D, Mutti E. New basis of the neurotrophic action of vitamin B12. *Clin Chem Lab Med* 2003;41:1435–7.
- [35] Mastronardi FG, Min W, Wang H, Winer S, Dosch M, Boggs JM, et al. Attenuation of experimental autoimmune encephalomyelitis and nonimmune demyelination by IFN-beta plus vitamin B12: treatment to modify notch-1/sonic hedgehog balance. *J Immunol* 2004;172:6418–26.